

CORRECTION

Open Access



# Correction: Atypical histological abnormalities in an adult patient with nephronophthisis harboring NPHP1 deletion: a case report

Maiko Akira<sup>1</sup>, Hitoshi Suzuki<sup>1\*</sup>, Arisa Ikeda<sup>1</sup>, Masako Iwasaki<sup>1</sup>, Daisuke Honda<sup>1</sup>, Hisatsugu Takahara<sup>1</sup>, Hisaki Rinno<sup>1</sup>, Shigeki Tomita<sup>2</sup> and Yusuke Suzuki<sup>3</sup>

**Correction: Nephrology 22, 261 (2021)**  
<https://doi.org/10.1186/s12882-021-02466-z>

Following publication of the original article [1], we found that there were misprint in the Fig. 2a. The correct Fig. 2 is given below:

The original article has been corrected.

Published online: 07 November 2023

## Reference

1. Akira M, et al. Atypical histological abnormalities in an adult patient with nephronophthisis harboring NPHP1 deletion: a case report. *BMC Nephrol.* 2021;22:261. <https://doi.org/10.1186/s12882-021-02466-z>.

The original article can be found online at <https://doi.org/10.1186/s12882-021-02466-z>.

\*Correspondence:

Hitoshi Suzuki  
shitoshi@juntendo.ac.jp

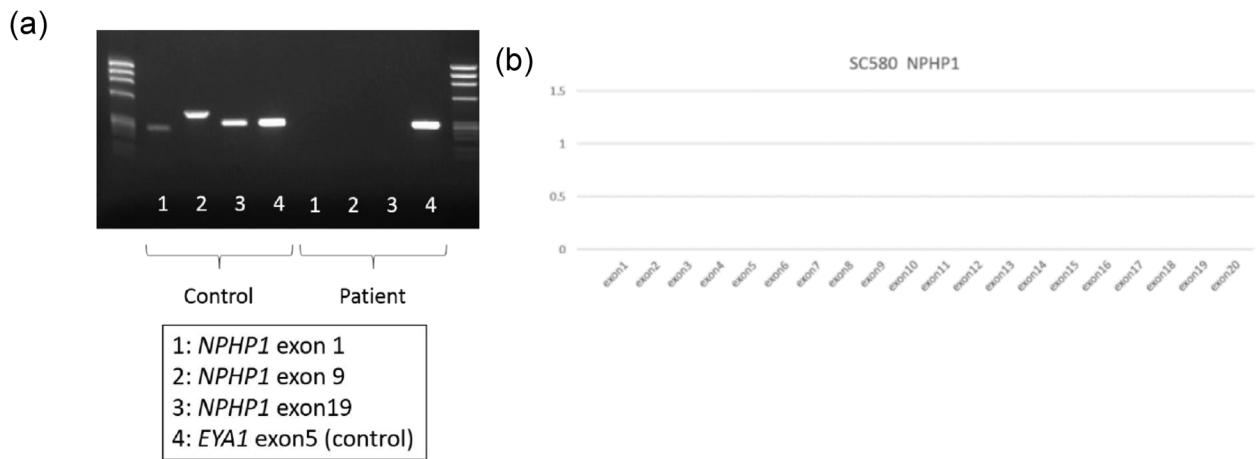
<sup>1</sup> Department of Nephrology, Juntendo University Urayasu Hospital, 2-1-1 Tomioka, Urayasu-Shi, Chiba 279-0021, Japan

<sup>2</sup> Department of Pathology, Juntendo University Urayasu Hospital, Chiba, Japan

<sup>3</sup> Department of Nephrology, Juntendo University Faculty of Medicine, Tokyo, Japan



© The Author(s) 2023. **Open Access** This article is licensed under a Creative Commons Attribution 4.0 International License, which permits use, sharing, adaptation, distribution and reproduction in any medium or format, as long as you give appropriate credit to the original author(s) and the source, provide a link to the Creative Commons licence, and indicate if changes were made. The images or other third party material in this article are included in the article's Creative Commons licence, unless indicated otherwise in a credit line to the material. If material is not included in the article's Creative Commons licence and your intended use is not permitted by statutory regulation or exceeds the permitted use, you will need to obtain permission directly from the copyright holder. To view a copy of this licence, visit <http://creativecommons.org/licenses/by/4.0/>. The Creative Commons Public Domain Dedication waiver (<http://creativecommons.org/publicdomain/zero/1.0/>) applies to the data made available in this article, unless otherwise stated in a credit line to the data.



**Fig. 2** Genetic analysis of the *NPHP1* gene. **a** No exons from *NPHP1* were amplified in this patient. **b** Multiplex ligation-dependent probe amplification analysis indicated complete deficiency of the *NPHP1* gene